

# A different airway management in double lumen tube intubation due to unexpected difficult airway

 Dilara Arıcan<sup>1</sup>,  Musa Zengin<sup>2</sup>,  Oya Kabal<sup>1</sup>,  Ramazan Baldemir<sup>1</sup>,  Ali Alagöz<sup>1</sup>

<sup>1</sup>Department of Anesthesiology and Reanimation, Ankara Atatürk Sanatorium Training and Research Hospital, University of Health Sciences, Ankara, Türkiye

<sup>2</sup>Department of Anesthesiology and Reanimation, Ankara Etlik City Hospital, Ankara, Türkiye

Received: 08/01/2024

Accepted: 29/01/2024

Published: 12/02/2024

**Cite this article:** Arıcan D, Zengin M, Kabal O, Baldemir R, Alagöz A. A different airway management in double lumen tube intubation due to unexpected difficult airway. *Eurasian J Anesthesiol Intens Care*. 2024;1(1):20-23.

**Corresponding Author:** Musa Zengin, musazengin@gmail.com

## ABSTRACT

A difficult airway is when an experienced anesthesiologist has difficulty in providing ventilation with a mask and/or endotracheal intubation. In cases where intubation cannot be achieved with laryngoscopy, devices such as laryngeal mask airway (LMA) or fiberoptic bronchoscope (FOB) can greatly contribute to the management of the difficult airway. This process may be further complicated when direct laryngoscopy and DLT intubation fail. In this case, the first goal should be to reach the airway. For this purpose, a single-lumen tube can be used first. Although there is not yet a clear algorithm for difficult intubation in DLT insertion, the gum elastic bougie (GEB) is widely used in clinical practice for this purpose. In this case report, we wanted to highlight two of our cases in which we encountered unexpected difficult intubation and we achieved successful endobronchial intubation with FOB-guided GEB through the LMA.

**Keywords:** Difficult intubation, difficult airway, laryngeal mask airway, double lumen tube, gum elastic bougie

## INTRODUCTION

A difficult airway is when an experienced anesthesiologist has difficulty in providing ventilation with a mask and/or endotracheal intubation. Its incidence varies between 1-13%.<sup>1</sup> It is estimated that half of these are unexpectedly difficult intubations. Many conditions such as congenital, anatomical and acquired factors may complicate airway management.<sup>2</sup> Failure to successfully manage the difficult airway is estimated to be responsible for 30% of anesthesia-related deaths. The patient's previous anesthesia experience allows us to obtain information about the airway and may guide a detailed evaluation of unexpected difficult airway and difficult intubation. In addition, to determine the possibility of difficult intubation, anesthetists use many measurement methods such as Mallampati (oropharyngeal view), sternomental distance, and thyromental distance in preoperative evaluation. In addition, the Cormack & Lehane test is used to evaluate the upper airways and vocal cords during laryngoscopy.<sup>3</sup> Although these tests and measurements are useful in predicting difficult intubation, many difficult intubation cases may occur after direct laryngoscopy is attempted to visualize the vocal cords after anesthesia induction. Endotracheal intubation is a standard method in general anesthesia practice. In cases where intubation cannot be achieved with laryngoscopy, devices such as laryngeal mask airway (LMA) or fiberoptic bronchoscope (FOB) can greatly contribute to the management of the

difficult airway.<sup>4</sup> FOB application is a reliable method used to perform procedures such as confirmation or repositioning of endotracheal tube placement, replacement of endotracheal tubes, placement of double lumen endotracheal tubes (DLT), and placement of endobronchial blockers. Although the LMA does not completely protect the airway against aspiration, it does allow ventilation and oxygenation.<sup>5</sup> DLT are very commonly used in surgical operations involving the thoracic cage. Insertion of DLT is more difficult than a standard endotracheal tube due to its size and shape.<sup>6</sup> This process may be further complicated when direct laryngoscopy and DLT intubation fail. Although there is not yet a clear algorithm for difficult intubation in DLT insertion, the gum elastic bougie (GEB) is widely used in clinical practice for this purpose.<sup>7</sup> However, although GEB contributes to the success of DLT intubation, there may be a risk of airway trauma due to blind application.<sup>7</sup> For this reason, it may be advantageous to apply the GEB application with FOB. Especially during difficult intubation, if airway safety can be achieved with LMA, FOB-guided GEB application may be beneficial to reduce airway trauma in these patients.

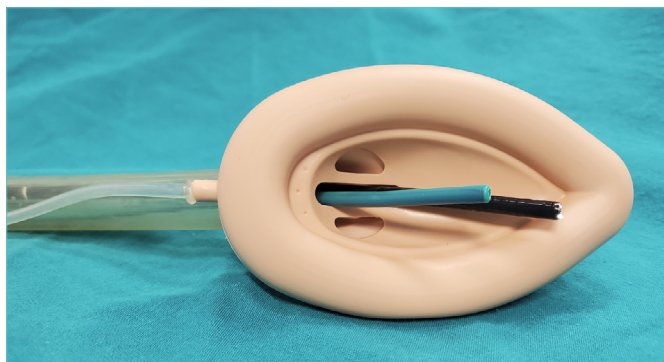
In this case report, we wanted to highlight two of our cases in which we encountered unexpected difficult intubation and we achieved successful endobronchial intubation with FOB-guided GEB through the LMA.

## CASE

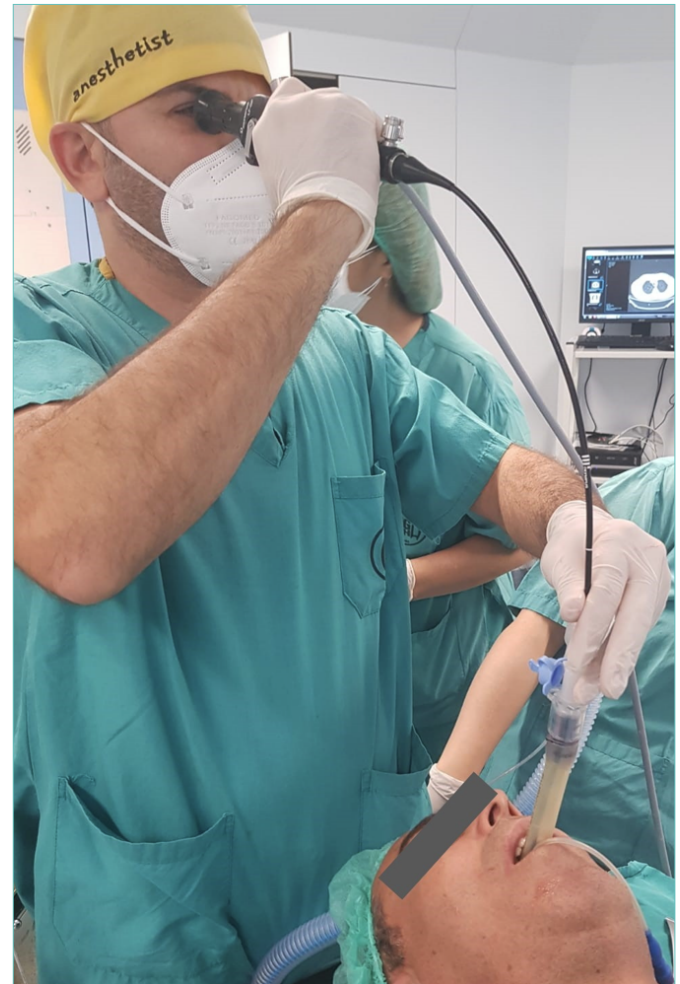**Case 1:** A 29-year-old 46 kg, 173 cm male patient who will be operated for pneumothorax was evaluated preoperatively. The patient had no known additional disease. The patient with normal preoperative laboratory parameters and stable vital signs was evaluated as American Society of Anesthesiologist (ASA) I. The patient's Mallampati score was 2 and there was no limitation in neck movements. The incisor distance was 5 cm. Also, thyromental and sternomental distances were 5 cm and 12 cm, respectively.

**Case 2:** A 56-year-old, 65-kg, 160-cm male patient who was planned to undergo VATS/thoracotomy due to a nodule in the lower lobe of the right lung was evaluated preoperatively. The patient had known hypertension disease. He had not undergone any previous surgical operation. The patient with normal preoperative laboratory parameters and stable vital signs was evaluated as ASA II. The patient's Mallampati score was 2 and there was no limitation in neck movements. The incisor distance was 6 cm. In addition, the thyromental and sternomental distances were 6 cm and 12 cm, respectively.

Both of the patients were pre-oxygenated with 100% oxygen after being monitored in the operating room according to standard ASA criteria before general anesthesia induction. Lidocaine (1 mg/kg), propofol (2 mg/kg), fentanyl (1 mg/kg), and vecuronium (0.1 mg/kg) were administered intravenously for anesthesia induction. An oral airway was placed. The patients were ventilated easily with a mask. Intubation was attempted with a laryngoscope (Heine, size 4) after 3 minutes in both patients; however, vocal cords could not be visualized. Cormack & Lehane scoring was determined as 4 for both patients. Intubation was attempted with a video laryngoscope (McGrath), but vocal cords could not be visualized in both patients. After a LMA was placed for both patients, the location of the vocal cords was determined by advancing the FOB through the LMA. The vocal cords were passed in a controlled manner by advancing the GEB next to the FOB (Figure 1). GEB was fixed and FOB and LMA were removed (Figure 2). Appropriate sized left DLT was directed through the GEB. The placement of DLT was first demonstrated with end-tidal CO<sub>2</sub> and then confirmed by performing FOB. Anesthesia was maintained with 50% O<sub>2</sub>, 50% air and 5-6% desflurane. Desaturation was not encountered during these procedures. The first patient's operation is approximately 120 minutes; In the second patient, it took 150 minutes. At the end of the case, the patients whose spontaneous respiration was returned with 2 mg/kg sugammadex were extubated without any problems and transferred to the postoperative recovery room.



**Figure 1.** Demonstrative view of passing gum elastic bougie and fiberoptic bronchoscopy through laryngeal mask airway



**Figure 2.** A fiberoptic bronchoscopy guided gum elastic bougie insertion through the laryngeal mask airway in a case of difficult double lumen tube intubation

## DISCUSSION

The difficult airway is one of the main causes of anesthesia-related morbidity and mortality. Difficult ventilation is defined as the inability of an experienced anesthesiologist to keep oxygen saturation above 90% using a face mask. Difficult intubation is defined as more than three attempts to intubate the trachea or requiring more than 10 minutes to complete the intubation, a condition that occurs between 1.5% and 8% of general anesthesia procedures.<sup>8</sup> Preoperative evaluation is crucial in predicting difficult intubation. Although there are national and international difficult airway algorithms; each clinic must create its own algorithm. Examination findings such as Mallampati scoring, sternomental and thyromental distance, anterior mandibular region anatomy, degree of extension of the head, and radiological examinations can be used to predict intubation difficulty.<sup>9</sup> The most widely used scale is the Mallampati test, which divides patients into four classes based on the visualization of the soft palate, uvula, and anterior and posterior pillar. In addition, several conditions that predispose patients to difficult intubation have been reported. These conditions include infections, trauma, obesity, endocrine factors, foreign body, tumors, inflammatory conditions, and congenital problems.<sup>10</sup>

In some cases, although patients can be easily ventilated with a mask, endotracheal intubation is not easily performed. This situation can be even more problematic especially in DLT applications. The incidence of intubation difficulty in patients with Cormack & Lehane classification 4, which indicates the

visualization of the vocal cords during laryngoscopy, varies between 1-4%.<sup>11</sup> In such cases, methods such as repositioning the head and neck, cricoid compression, inserting a guide into the ETT, and using GEB can be tried.<sup>10</sup> If these methods are not successful, intubation can be performed using LMA, retrograde intubation, FOB, and video laryngoscope.<sup>12</sup> Conditions such as tachycardia, hypertension, increased intracranial pressure that develop with repetitive interventions may cause failure, especially in patients with limited cardiac reserve. This is especially important in thoracic surgery cases where respiratory problems are at the forefront. Therefore, in our cases, while avoiding hypoxia by providing airway patency with LMA instead of repetitive intubation attempts; By advancing GEB with FOB, we also protected it from respiratory tract traumas that may be caused by GEB.

A single airway test cannot provide a high index of sensitivity and specificity for predicting difficult airways. For this reason, a combination of multiple tests is often used. Shiga et al.<sup>1</sup> in a meta-analysis, differences were identified in the use of tests to detect difficult intubation before surgery, alone and in combination. They found that while the sensitivity of the tests alone was weak to moderate, the diagnostic value increased when used in combination.<sup>13</sup> Difficult intubation was not expected in our two cases, since the Mallampati score was determined as two and the thyromental-sternomental distances were normal. Although the multiple tests used are thought to be more valuable, such tests cannot prevent the unpredictable intubation difficulty. For this reason, one should be prepared for the difficulties of intubation and airway management, especially in situations where intubation can be performed more difficult, such as DLT. In this regard, institute-based algorithms can play an important role in success. Kheterpal et al.<sup>13</sup> was reported in a study by 77 of 53041 patients that difficulty in mask ventilation was experienced, difficult intubation was encountered in 19 patients, and alternative difficult airway methods were applied in 12 patients. GEB, which has pediatric and adult forms, has been used for a long time in cases of unexpected difficult intubation. The tip of the GEB has an angle to target the tracheal opening. However, blind applications of GEB may lead to catastrophic traumas in the upper airways and especially in the trachea. Kadry et al.<sup>14</sup> presented a case report in which they perforated the larynx wall while trying to intubate blindly with GEB in a patient who developed an unexpected difficult airway and difficult intubation. We could not provide intubation in both of our cases, and we performed controlled endotracheal intubation with FOB and GEB over LMA.

When difficult intubation is encountered under general anesthesia, LMA application is one of the options in the difficult airway algorithm to provide an alternative airway. LMA is a supraglottic airway device developed by British anesthesiologist Dr. Archie Brain. It has been used since 1981.<sup>15</sup> It has recently been used in emergencies. This is because it is easy and fast to use, even for inexperienced anesthesiologists. While intubation with FOB remains the preferred option for many anesthesiologists, the LMA and its modifications provide equal or better conditions for intubation compared to the awake FOB technique.<sup>16</sup> We also advanced the GEB into the trachea under the guidance of FOB, under the control of the LMA. Thus, we were able to perform visual endotracheal intubation, protected from traumatic complications that may be caused by GEB.

DLT is the gold standard in airway management for thoracic surgery operations. DLT is more difficult to insert than a standard tracheal tube due to the larger DLT dimensions. During intubation with DLT, the use of GEB may facilitate intubation.<sup>17</sup> Thus, complications such as bleeding and edema caused by failed and repeated intubation attempts can be reduced.

Wong et al.<sup>18</sup> in their study, compiled two studies in which intubation with a single lumen tube was performed by advancing FOB and GEB together through the LMA. However, to our knowledge, there is no other literature in which the same method is performed with DLT. Information on the successful use of the video laryngoscope and FOB for DLT placement in the unexpectedly difficult intubation situation is still limited. There are no accepted guidelines yet for difficult intubation situations when using DLT. A recent review considered an algorithm for thoracic surgery involving the use of introducers such as GEB for unexpectedly difficult intubation.<sup>19</sup> Watson et al.<sup>20</sup> described two difficult intubation patients who tried blind intubation with FasTrach TM and succeeded after failed intubation with FOB.

## CONCLUSION

The main task of anesthesiologists is to solve problems that may develop perioperatively. Airline safety is one of the most important components of this management. Preoperative evaluations used to predict airway problems, although instructive, can be misleading from time to time. Repetitive intubation attempts due to difficult airway and intubation may cause serious problems, especially in patients with a limited respiratory reserve and accompanying comorbidities. Therefore, instead of repetitive intubation and long-term mask application, it may be a different and safe alternative to secure the airway with the LMA, and to place the pediatric GEB through the LMA with FOB into the trachea.

## ETHICAL DECLARATIONS

### Informed Consent

All patients signed and free and informed consent form.

### Referee Evaluation Process

Externally peer-reviewed.

### Conflict of Interest Statement

The authors have no conflicts of interest to declare.

### Financial Disclosure

The authors declared that this study has received no financial support.

### Author Contributions

All of the authors declare that they have all participated in the design, execution, and analysis of the paper, and that they have approved the final version.

## REFERENCES

1. Shiga T, Wajima Z, Inoue T, Sakamoto A. Predicting difficult intubation in apparently normal patients: a meta-analysis of bedside screening test performance. *Anesthesiol*. 2005;103(2):429-437. doi: 10.1097/00000542-200508000-00027

2. Cattano D, Panicucci E, Paolicchi A, Forfori F, Giunta F, Hagberg C. Risk factors assessment of the difficult airway: an Italian survey of 1956 patients. *Anesth Analg*. 2004;99(6):1774-1779. doi: 10.1213/01.ANE.0000136772.38754.01
3. Mallampati SR, Gatt SP, Gugino LD, et al. A clinical sign to predict difficult tracheal intubation: a prospective study. *Can Anaesth Soc J*. 1985;32(4):429-434. doi: 10.1007/BF03011357
4. Williams PJ, Bailey PM. Management of failed oral fiberoptic intubation with laryngeal mask airway insertion under topical anaesthesia. *Can J Anaesth*. 1993;40(3):287. doi: 10.1007/BF03037045
5. Runciman WB, Kluger MT, Morris RW, Paix AD, Watterson LM, Webb RK. Crisis management during anaesthesia: the development of an anaesthetic crisis management manual. *Qual Saf Health Care*. 2005;14(3):e1. doi: 10.1136/qshc.2002.004101
6. Benumof JL. Difficult tubes and difficult airways. *J Cardiothorac Vasc Anesth*. 1998;12(2):131-132. doi: 10.1016/s1053-0770(98)90317-2
7. Stix MS, Ata S, Wolckenhaar M, Kaufman MD. Double-lumen tubes: which lumen for the gum elastic bougie? *Anesth Analg*. 2010;110(1):258-259. doi: 10.1213/ANE.0b013e3181c293cf
8. Paix AD, Williamson JA, Runciman WB. Crisis management during anaesthesia: difficult intubation. *Qual Saf Health Care*. 2005;14(3):e5. doi: 10.1136/qshc.2002.004135
9. Brain AI, Verghese C, Addy EV, Kapila A, Brimacombe J. The intubating laryngeal mask. II: a preliminary clinical report of a new means of intubating the trachea. *Br J Anaesth*. 1997;79(6):704-709. doi: 10.1093/bja/79.6.704
10. Roth D, Pace NL, Lee A, et al. Airway physical examination tests for detection of difficult airway management in apparently normal adult patients. *Cochrane Database Syst Rev*. 2018;5:CD008874. doi: 10.1002/14651858.CD008874.pub2
11. Çeliker V, Çelebi N, Uzun Ş. Zor Havayolu ve Yönetimi. *Türkiye Klin J Surg Med Sci*. 2006;2:40-46.
12. Apfelbaum JL, Hagberg CA, Caplan RA, et al. American Society of Anesthesiologists task force on management of the difficult airway. Practice guidelines for management of the difficult airway: an updated report by the American Society of Anesthesiologists task force on management of the difficult airway. *Anesthesiol*. 2013;118(2):251-270. doi: 10.1097/ALN.0b013e31827773b2
13. Kheterpal S, Martin L, Shanks AM, Tremper KK. Prediction and outcomes of impossible mask ventilation: a review of 50,000 anesthetics. *Anesthesiol*. 2009;110(4):891-897. doi: 10.1097/ALN.0b013e31819b5b87
14. Kadry M, Popat M. Pharyngeal wall perforation--an unusual complication of blind intubation with a gum elastic bougie. *Anaesthesia*. 1999;54(4):404-405. doi: 10.1046/j.1365-2044.1999.00876.x
15. van Zundert TCRV, Brimacombe JR, Ferson DZ, Bacon DR, Wilkinson DJ. Archie Brain: celebrating 30 years of development in laryngeal mask airways. *Anaesthesia*. 2012;67(12):1375-1385. doi: 10.1111/anae.12003.x
16. Barash BG, Cullen BF, Stoelting RK, Cahalan MK, Stock MC. *Klinik Anestezi*. 5<sup>th</sup> ed. Nobel Tıp Kitabevi: 2012.
17. Kumar R, Prashast, Wadhwa A, Akhtar S. The upside-down intubating laryngeal mask airway: a technique for cases of fixed flexed neck deformity. *Anesth Analg*. 2002;95(5):1454-1458. doi: 10.1097/00000539-200211000-00066
18. Wong DT, Yang JJ, Mak HY, et al. Use of intubation introducers through a supraglottic airway to facilitate tracheal intubation: a brief review. *Can J Anaesth*. 2012;59(7):704-715. doi: 10.1007/s12630-012-9714-8
19. Tunç M, Sazak H, Baldemir R, Alagöz A. Unexpected difficult intubation with a double-lumen tube in a case of asymptomatic vallecular cyst. *Türk J Anaesthesiol Reanim*. 2021;49(4):334-337. doi: 10.5152/TJAR.2021.291
20. Watson NC, Hokanson M, Maltby JR, Todesco JM. The intubating laryngeal mask airway in failed fiberoptic intubation. *Can J Anaesth*. 1999;46(4):376-378. doi: 10.1007/BF03013232