MHA MEDIHEALTH ACADEMY

Eurasian Journal of
Anesthesiology & Intensive Care

Case Report

doi
10.51271/EAJAIC-0063

Suspected indirect pesticide exposure associated with multiorgan dysfunction after consumption of wild asparagus: a case report

Veysel Garani Soylu*[1], Esra Polat[2], Öztürk Taşkın[3], Ufuk Demir[3], Büşra Tanyıldızı Küçük[3]

[1]Department of Intensive Care, Faculty of Medicine, Kastamonu University, Kastamonu, Turkiye
[2]Department of Anesthesiology and Reanimation, Faculty of Medicine, Kırıkkale University, Kırıkkale, Turkiye
[3]Department of Anesthesiology and Reanimation, Faculty of Medicine, Kastamonu University, Kastamonu, Turkiye

Cite this article: Soylu VG, Polat E, Taşkın Ö, Demir U, Tanyıldızı Küçük B. Suspected indirect pesticide exposure associated with multiorgan dysfunction after consumption of wild asparagus: a case report. *Eur J Anesthesiol Intens Care.* 2026;3(4):108-111. doi:10.51271/EAJAIC-0063

***Corresponding Author:** Veysel Garani Soylu, vgsoylu@hotmail.com

Received: 29/07/2026 ◆ **Accepted**: 09/09/2026 ◆ **Published**: 23/11/2026

ABSTRACT

Indirect poisoning is a rare condition causing multiple organ failure (MOF) of unknown cause. In this study, we aimed to present a rare case of suspected pesticide poisoning due to indirect contamination, a clinically unpredictable condition, in a patient admitted to our intensive care unit with MOF of unknown cause, and to raise awareness among clinicians in this context. A 73-year-old female patient with no known underlying medical condition presented to the emergency department with complaints of weakness and shortness of breath. Following clinical and laboratory evaluation, the patient was admitted to the intensive care unit due to unexplained MOF affecting the respiratory, renal, hepatic, hematological, and cardiac systems. Since a clear etiological cause could not be determined in the initial evaluations, the patient's environmental exposure was investigated, and after further investigation of the anamnesis, it was suspected that there was indirect pesticide exposure, and the patient was successfully treated with supportive treatment guided by the clinical presentation. Indirect pesticide exposure, particularly when it occurs after consuming pesticide-contaminated wild plants, can present clinicians with a rare clinical condition that is easily overlooked but can lead to life-threatening multiple organ failure.

Keywords: Pesticides, multiple organ failure, dietary exposure, intensive care units

INTRODUCTION

Pesticides are a broad group of chemical compounds used to control, remove, or eliminate non-target harmful organisms.[1,2] Acute pesticide poisonings resulting from the widespread use of these substances remain a serious global public health problem and one of the leading causes of emergency room visits.[1] Exposure to toxic agents usually occurs intentionally (for suicidal purposes) or accidentally (occupational or environmental). In intentional ingestions, the active substance can often be clearly identified by the patient or their relatives; however, in accidental exposures, there is generally insufficient and limited data on the type, amount, and duration of exposure to the chemical.[3] In medical literature and clinical practice, the usual scenario is cases that develop through direct contact with the toxic agent. In contrast, identifying contaminations and exposures that occur indirectly is a complex and challenging diagnostic process for clinicians. One of the most critical steps in determining clinical success and prognosis in pesticide poisonings is the specific identification of the chemical agent to which the patient is exposed and the selection of appropriate antidotes or elimination methods. However, acute management of cases suspected of poisoning but where the toxic agent has not yet been clinically or laboratory confirmed presents serious challenges. In cases admitted to intensive care units where poisoning is suspected clinically but the agent cannot be identified, the basic approach is stabilization of the patient's vital functions, resuscitation, and aggressive supportive treatment.[4] In this acute period where the chemical agent cannot be clarified, the "toxidromic approach," focusing on the patient's clinical findings and systemic symptoms, comes to the forefront in the diagnostic and treatment algorithm.[5]

Acute poisonings are clinical conditions that can rapidly progress to multiple organ failure (MOF) and require close invasive monitoring in intensive care settings. The most vital point here is that the clinician should consider the

This work is licensed under the Creative Commons Attribution-NonCommercial-NoDerivatives 4.0 International License.

possibility of "poisoning" behind the atypical picture that leads the patient to MOF in the early stages. With this case presentation; We aimed to present a rare case of suspected pesticide poisoning due to indirect contamination, a clinically unpredictable condition, in a patient admitted to our intensive care unit with MOF of unknown cause, and to raise awareness among clinicians in this context.

CASE REPORT

A 73-year-old female patient with no known underlying medical conditions presented to the emergency department with complaints of weakness and shortness of breath. Her history revealed that her symptoms began on the day of admission and that she had no prior similar complaints. Her vital signs at admission were: pulse 105 beats/minute, respiratory rate 24/minute, blood pressure 145/75 mmHg, body temperature 36.3°C, and peripheral oxygen saturation (SpO_2) 84%. Physical examination revealed no additional pathological findings except for bilateral decreased lung sounds. Initial laboratory investigations showed. White blood cell count was 7.7×10^3/µL, neutrophil count was 72%, hemoglobin was 12.1 g/dl, hematocrit was 35.6%, platelet count was 88×10^3/µL, glucose was 130 mg/dl, creatinine was 2.77 mg/dl, urea was 61 mg/dl, ALT was 253 U/L, AST was 286 U/L, total bilirubin was 9.2 mg/dl, direct bilirubin was 3.4 mg/dl, albumin was 3.9 g/dl, C-reactive protein (CRP) was 18 mg/L, activated partial thromboplastin time (aPTT) was 42.7 seconds, and high-sensitivity troponin I (hs-Troponin I) was 2406 ng/L. Arterial blood gas analysis in room air showed pH 7.40, PaO_2 51 mmHg, $PaCO_2$ 29.4 mmHg, HCO_3 19.4 mmol/L, oxygen saturation 86%, and lactate 2.8 mmol/L, consistent with hypoxemic respiratory failure.

Abdominal computed tomography revealed no pathological findings. Thoracic computed tomography showed interlobular septal thickening, approximately 2.5 cm pleural effusion in the right hemithorax and approximately 1 cm pleural effusion in the left hemithorax, bilateral atelectatic changes in the basal areas, and peripherally located patchy ground-glass opacities in the upper zones (Figure).

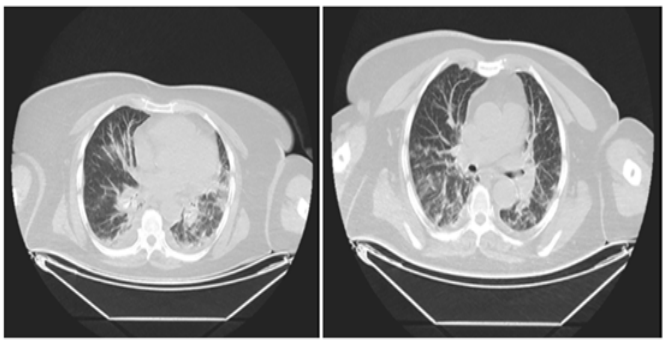

Figure. Thoracic CT scan image of the patient upon admission to the emergency department
CT: Computed tomography

Bedside echocardiographic evaluation revealed a left ventricular ejection fraction of 60%. No left ventricular wall motion abnormality, significant valvular pathology, or significant cardiac dysfunction was detected. Systolic pulmonary artery pressure was measured as 35 mmHg.

The patient was admitted to the intensive care unit due to unexplained multiple organ dysfunction affecting the respiratory, renal, hepatic, hematological, and cardiac systems. Supportive treatment was initiated, and high-flow nasal oxygen therapy was started. Since no clear etiological cause could be identified in the initial assessments, the patient's environmental exposure history was re-examined in detail. It was learned that the patient consumed wild *Asparagus officinalis*, which she had collected from his region (Tosya district, Kastamonu province) and consumed safely for many years, on the day of admission. Furthermore, the patient stated that the agricultural land where the plants were collected had been sprayed with pesticides approximately two days prior to combat harmful insects and weeds, and that rain had occurred in the area after the spraying. Therefore, it was considered that the consumed wild asparagus may have been contaminated with pesticides. The patient stated that she had eaten wild asparagus approximately 8 hours before arriving at the hospital, that she couldn't remember how much she had consumed, and that no one else had eaten the same plant. Considering the patient's history of environmental exposure, clinical presentation with multi-organ involvement, and laboratory findings, a preliminary diagnosis of indirect and suspected pesticide exposure due to consumption of pesticide-contaminated wild asparagus was considered. Sepsis, infection, viral, biliary tract, hematological, ischemic cardiac, and autoimmune causes that could lead to MOF in the patient were ruled out through anamnesis, clinical, laboratory, and radiological examinations. The pesticide agent could not be confirmed due to the inability to perform toxicological analyses to determine the pesticide type at our center. Therefore, the patient received symptomatic and supportive treatment.

During the first 24 hours of intensive care monitoring, the patient developed anuria and her serum creatinine level rose to 4.89 mg/dl, prompting the initiation of intermittent renal replacement therapy. On the seventh day of intensive care treatment, a significant improvement was observed in the patient's respiratory function and liver function tests. The room air SpO_2 value was measured as 93%. In control laboratory investigations; The following values were determined: white blood cell count 8.1×10^3/µL, neutrophil percentage 68%, hemoglobin 12.7 g/dl, hematocrit 36.7%, platelet count 184×10^3/µL, glucose 152 mg/dl, creatinine 3.8 mg/dl, urea 44 mg/dl, ALT 22 U/L, AST 28 U/L, total bilirubin 2.2 mg/dl, direct bilirubin 0.8 mg/dl, albumin 3.6 g/dl, CRP 11 mg/L, aPTT 28.2 seconds, and hs-troponin I 265.3 ng/L. Control arterial blood gas analysis showed pH 7.35, PaO_2 88.2 mmHg, $PaCO_2$ 36.4 mmHg, HCO_3 19.8 mmol/L, oxygen saturation 92%, and lactate 1.2 mmol/L. Although significant improvement was observed in liver and respiratory function, improvement in renal function was delayed, and intermittent renal replacement therapy was continued due to anuria and overload. The patient was transferred to the internal medicine ward on the tenth day of intensive care. On the fifth day of ward observation, spontaneous urine output resumed, and gradual improvement in renal function was observed. The patient's serum creatinine level decreased to 1.45 mg/dl, and on the tenth day of ward observation, the patient was discharged in a clinically stable condition.

DISCUSSION

Pesticide poisoning remains a significant public health problem worldwide, with the vast majority of cases developing as a result of intentional ingestion, occupational exposure, or direct contact with pesticides.[6] In contrast, indirect exposures resulting from the consumption of pesticide-contaminated food are rarer and clinically difficult to recognize. In this case, we share a patient with multiple organ dysfunction resulting from indirect poisoning a difficult-to-predict clinical condition after consuming wild *Asparagus officinalis* collected from a pesticide-treated agricultural area, even though the patient did not have direct contact with the pesticide.

The clinical manifestations of pesticide poisoning show a wide spectrum depending on the class of agent, the dose, the route of exposure, and the individual characteristics of the patient. Although different pesticide groups such as organophosphates, carbamates, pyrethroids, and glyphosate have different toxicity mechanisms, the common end pathway in severe cases is oxidative stress, mitochondrial dysfunction, endothelial damage, and systemic inflammatory response. As a result of these mechanisms, the renal, hepatic, pulmonary, and cardiac systems are affected simultaneously. In our case, there were also findings of multisystemic toxic involvement (acute kidney injury, hepatocellular damage, hypoxemic respiratory failure, thrombocytopenia, and marked troponin elevation), and these findings showed that the patient had this clinical picture as a result of poisoning. Acute kidney injury is one of the most important mortality determinants of pesticide poisoning. Toxic agents can directly cause tubular cell damage, as well as impair kidney function through renal perfusion disorder, oxidative stress, rhabdomyolysis, and microvascular damage.[7] Early initiation of renal replacement therapy, especially in cases presenting with oliguria or anuria, is important for preventing metabolic complications. In our patient, renal replacement therapy was applied due to anuria and progressive creatinine elevation that developed within the first 24 hours, and kidney function recovered later than other organ systems. This situation is consistent with publications showing that renal recovery may be delayed in pesticide-related acute kidney injury.[8]

In this case, the diagnosis causing MOF was made thanks to a detailed environmental exposure history. At the time of admission, the patient herself was unaware of pesticide exposure, and no etiological cause that could explain the multiple organ failure was identified in the initial assessment. Indirect poisoning is a clinical situation that is difficult for clinicians to consider in patients with unexplained multiple organ dysfunction, and a detailed nutritional history, environmental exposure inquiry, and toxidromic approach are critical factors in reaching the diagnosis.[9]

Toxicological analyses to determine pesticide levels or pesticide class cannot be performed at our center. Therefore, the pesticide agent to which the patient was exposed could not be confirmed in the laboratory. The lack of toxicological analysis can be noted as a limitation for our case presentation. The diagnosis of indirect pesticide poisoning due to the patient's consumption of pesticide contaminated wild asparagus was made by evaluating the patient's detailed exposure history, the exclusion of alternative etiologies, the consistency of clinical findings with multisystemic toxicity, and the clinical improvement observed with supportive treatment. In a comprehensive review published in the literature, 63 different outbreaks related to foodborne pesticide exposure were evaluated, and it was stated that most of these events developed as a result of the misuse of pesticides, failure to comply with harvest time, or accidental contamination of food.[10] In our literature search, we did not encounter any cases of indirect poisoning except for the case of Anticholinergic Toxic Syndrome Developed as a Result of Indirect Exposure to Hyoscyamus muticus by Ingesting Locusts, published by Mohammad Halawani in 2025.[11] To our knowledge, our case is; This is the only case of MOF developing after pesticide contamination of wild-collected edible plants. Therefore, this case report makes a significant contribution to the literature by demonstrating that clinicians should consider not only occupational or direct pesticide exposure but also indirect exposure from wild plants collected from agricultural areas in the differential diagnosis. Our case differs from the existing literature in several aspects. First, our patient did not have direct contact with the pesticide; it is a case of indirect pesticide exposure after consuming wild *Asparagus officinalis* collected from a pesticide-treated agricultural area. In the literature, classic cholinergic side effects are seen in pesticide poisoning cases. In our case, initially unexplained hypoxemic respiratory failure, acute renal injury, hepatic dysfunction, etc. The clinical picture was characterized by multiple organ dysfunction accompanied by thrombocytopenia and myocardial damage. This constitutes an atypical clinical presentation that can lead to a delay in diagnosis. With these features, our case demonstrates that a detailed history can be as important as laboratory investigations, especially in emergency department and intensive care unit practice.

CONCLUSION

Indirect pesticide exposure, particularly when occurring after consumption of contaminated wild plants, is a rare clinical condition that can be easily overlooked but can lead to life-threatening multi-organ failure. Clinicians should consider possible indirect toxic exposure and obtain a detailed dietary and environmental history in patients presenting with otherwise unexplained multiorgan dysfunction. Increasing clinical awareness is crucial for the early recognition and appropriate management of similar cases.

ETHICAL DECLARATIONS

Informed Consent

Written informed consent was obtained from the patient included in this report. Signed consent forms are retained by the authors and are available upon request.

Peer Review Process

This report underwent external peer review.

Conflict of Interest

The authors declare no conflicts of interest.

Financial Disclosure

This case report did not receive any financial support.

Author Contributions

Concept: VGS; Design: VGS; Control: VGS, EP; Resources: VGS, ÖT, UD, BTK; Materials: VGS, EP; Data Collection and/ or Processing: VGS, EP; Analysis and/or Interpretation: VGS, ÖT, UD, BTK; Literature Review: VGS; Article Writing: VGS; Critical Review: VGS, ÖT, UD, BTK.

REFERENCES

1. Gou X, He X, Li N, He J, Wang Y, Tian W. Characteristics and trends of acute poisoning in emergency departments: a single-center retrospective study in Zunyi, China (2021-2024). *Front Public Health*. 2026;14:1816492. doi:10.3389/fpubh.2026.1816492
2. Garud A, Pawar S, Patil MS, Kale SR, Patil S. A scientific review of pesticides: classification, toxicity, health effects, sustainability, and environmental impact. *Cureus*. 2024;16(8):e67945. doi:10.7759/cureus.67945
3. Chien WC, Chung CH, Jaakkola JJK, et al. Risk and prognostic factors of inpatient mortality associated with unintentional insecticide and herbicide poisonings: a retrospective cohort study. *PLoS One*. 2012;7(9):e45627. doi:10.1371/journal.pone.0045627
4. Hüser C, Bethlehem C, Dünser MW, et al; ESICM Trauma, Emergency Medicine Section. Critical care management of the patient with pharmaceutical poisoning. *Intensive Care Med*. 2025;51(12):2378-2391. doi:10.1007/s00134-025-08176-6
5. Reynolds S, Ramsden N, Richens N. Management of patients with suspected but unidentified poisoning in the emergency department (Royal College of Emergency Medicine best practice guideline 2025). *Arch Dis Child Educ Pract Ed*. 2026;111(4):161-165. doi:10.1136/archdischild-2025-329469
6. Baudry J, Rebouillat P, Samieri C, Berlivet J, Kesse-Guyot E. Dietary pesticide exposure and non-communicable diseases and mortality: a systematic review of prospective studies among adults. *Environ Health*. 2023;22(1):76. doi:10.1186/s12940-023-01020-8
7. Lewington AJP, Cerdá J, Mehta RL. Raising awareness of acute kidney injury: a global perspective of a silent killer. *Kidney Int*. 2013;84(3):457-467. doi:10.1038/ki.2013.153
8. Cerdá J, Bagga A, Kher V, Chakravarthi RM. The contrasting characteristics of acute kidney injury in developed and developing countries. *Nat Clin Pract Nephrol*. 2008;4(3):138-153. doi:10.1038/ncpneph0722
9. Valcke M, Levasseur ME, Soares da Silva A, Wesseling C. Pesticide exposures and chronic kidney disease of unknown etiology: an epidemiologic review. *Environ Health*. 2017;16(1):49. doi:10.1186/s12940-017-0254-0. Published correction appears in *Environ Health*. 2017;16(1):67. doi:10.1186/s12940-017-0274-9
10. Ferrer A, Cabral R. Toxic epidemics caused by alimentary exposure to pesticides: a review. *Food Addit Contam*. 1991;8(6):755-775. doi:10.1080/02652039109374034
11. Halawani M. Anticholinergic toxidrome following indirect exposure to *Hyoscyamus muticus* through grasshopper ingestion: a case report. *Cureus*. 2025;17(12):e100166. doi:10.7759/cureus.100166